

RUPTURED ANEURYSM OF THE SINUS OF VALSALVA

Dr. Özgül Uçar, Dr. Mehmet Koray Gürsel, *Dr. Nesligül Yıldırım, Dr. Sinan Aydoğdu

*Türkiye Yüksek İhtisas Hastanesi, Kardiyoloji Bölümü, Ankara Numune Hastanesi Kardiyoloji Bölümü, ANKARA

Bu vaka sunumunda, sağ atriyuma sağ valsalva sinüs anevrizma rüptürünün abdominal ağrı ile seyrettiği bir hasta takdim edilmiştir. Valsalva sinüs anevrizma rüptürleri genellikle göğüs ağrısı ve nefes darlığı ile presente olmakla birlikte, bu vakada olduğu gibi atipik semptomlar

görülebilmektedir.

Anahtar Kelimeler: Valsalva sinüs anevrizma rüptürü, Aorta-atrilyal fistül

(Türk Girişimsel Kard. Der. 2007;11: 90)

CASE REPORT

A 28-year-old Caucasian man presented with the complaints of abdominal pain and shortness of breath. His complaints had begun after strenuous work.

In a local hospital, he was diagnosed as having acute abdomen. A cardiac murmur was also heard and the patient was referred to our hospital for further investigation. He had no history of a cardiac disease. On physical examination a harsh, continuous murmur could be heard at the left sternal border.

The liver enzymes were elevated. Two-dimensional transthoracic and following transesophageal echocardiography revealed a ruptured aneurysm of the right sinus of Valsalva into the right atrium with the characteristic 'windsock' appearance (Figure 1).

On color Doppler a shunt from aorta to the right atrium via the fistula was detected (Figure 2). The patient went on an operation and the fistula was repaired by using a pericardial patch. Abdominal pain was due to hepatic congestion.

Although the most common presenting symptoms of a ruptured aneurysm of the sinus of Valsalva are chest pain and dyspnea, unusual symptoms as in this case can be seen.

Yazışma adresi: Dr. Nesligül YILDIRIM
Öveçler 8. cadde No: 55/13
Dikmen/ANKARA
Tel: +90 312 472 34 98
e-mail: nesligul2004@hotmail.com

Figure 1: Transesophageal echocardiogram revealing ruptured aneurysm of right sinus of Valsalva into the right atrium with characteristic 'windsock' appearance.

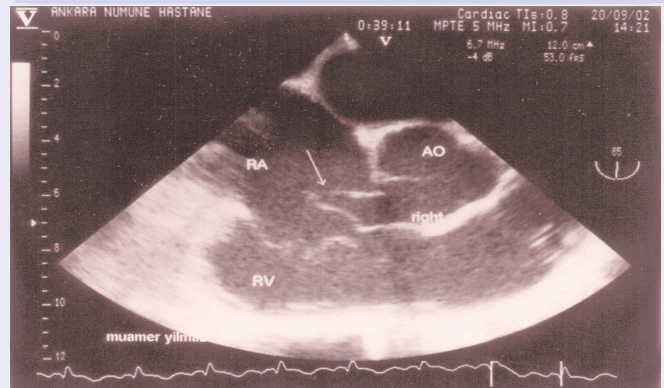


Figure 2: On color Doppler a shunt from aorta to the right atrium via the fistula is seen.

